

Original Article

Title:

**TRANSORAL SUBMANDIBULAR SIALOADENECTOMY;
FEASIBILITY AND CASE SELECTION.**

Authors:

Ehab M. Oraby

Assistant Professor of General Surgery, General Surgery Department, Benha Faculty of Medicine.

Mohammad I. Aburezk

Lecturer of General Surgery, General Surgery Department, Benha Faculty of Medicine.

Mokhtar A. Bahbah

Assistant Professor of General Surgery, General Surgery Department, Benha Faculty of Medicine.

mokhtar_bahbah@yahoo.com

Number of pages: 16

Number of photographs: 4

Word counts for abstract: 116

Word counts for text: 1618

Conflict of interest: NIL

Running title: *Transoral Sialoadenectomy*

Corresponding author: *Ehab Mahroos Oraby*

Assistant Professor of General Surgery, General Surgery Department, Benha Faculty of Medicine, Benha University, Fareed Nada Street, Benha, Egypt

Tel: +20 100 378 3425

fax: 3225509

e-mails: ehab.arabi@fmed.bu.edu.eg

ehaboraby2000@gmail.com

Transoral Submandibular Sialoadenectomy; Feasibility and Case Selection.

Abstract:

Introduction: The last century gave born to the concept of minimal invasive surgery and the scarless operations. The transoral approach targeted mainly the concept of scarless surgery in addition to keep the marginal mandibular nerve safe. Many limitations are facing the transoral approach as pathology type, lump size, lump mobility, and enough workspace.

Patients and methods: This prospective study was carried out on 20 consecutive patients. All of them presented with submandibular salivary gland swelling. All swellings included should be mobile, 2 cm or less, and patient showed positive 3-fingers test.

Conclusion: In selected cases, transoral approach can be a good alternative specially with those patients who are strongly appreciating scarless operations as young age females.

Key Words: *Scarless surgery, Transoral Sialoadenectomy, Submandibular Salivary Gland.*

Introduction:

Over the last century, a big shift has happened in the surgeons' orientation and patients' concern. Surgeons are paying every effort to achieve the most effective, less invasive, and more cosmetic procedures. On the other hand, patients raised their attention toward the aesthetic aspect of each procedure. These interactions gave born to the concept of minimal invasive surgery and the scarless operations(1,2).

In 1954, a dental surgeon Downton, during his work to reconstruct cases of alveolar atrophy, noted the possibility to excise the submandibular gland through the oral cavity after he cut the mylohyoid border. Downton and Qvist reported their proposed technique in 1960(3). Since that time, the proposed technique started to gain some popularity after Hong and Kim report in 2000.

Many procedures were described for submandibular sialoadenectomy. The standard technique is still the transcervical conventional sialoadenectomy. This conventional approach offers the direct

access with cumulated experience and low incidence of complications(4,5). The most prominent negative point in this technique is its scar which lies in a very exposed area and is going to be not accepted anymore by cosmetically oriented patients(1,5). Although neurological insult after this approach is low especially with experienced hands, but still happening especially the injury to marginal mandibular nerve. Also, remnant of submandibular duct may induce repeated intraoral infection or cysts(4–7).

In this context, surgeons tried to modify and/or find alternatives. Some procedures targeted to hide the scar through facelift postauricular incision(5,6). Others tried to make smaller wounds by the aid of endoscopic and even robotic instruments(1,5,8). This era refreshed the idea of transoral approach. Even in the transoral approach, many variations developed. Either by regular instruments or through endoscopic or robotic instruments(7–9).

The transoral approach targeted mainly the concept of scarless surgery in addition to keep the marginal mandibular nerve safe. On the other hand, this approach is giving a very high incidence of lingual nerve affection but fortunately, temporary affection. Also, it has some drawbacks with wound healing and tongue movements(3,4,7).

Many limitations are facing the transoral approach. These limitations are pathology type(5), lump size(9), lump mobility(4), and enough workspace. This workspace is much affected by factors such as tongue size, maximal mouth opening, and presence of molar teeth(3,7,10,11).

Patients and Methods:

This prospective study was conducted at Department of General Surgery, Benha University Hospital after obtaining approval from local ethical committee and after fully informed written

consent signed by patient. This study carried out on 20 consecutive patients. All of them presented with submandibular salivary gland swelling, from January 2018 to October 2021.

Inclusion Criteria:

Mobile swelling, its size not more than 2 cm. maximal mouth opening can admit the three middle fingers of the patient hand (3 finger test). Inflammatory or benign pathology.

Exclusion Criteria:

Swelling size more than 2 cm, fixed swelling, repeated attacks of sialadenitis, malignant lesions, big tongue, maximal mouth opening not admitting three fingers.

Operative Technique:

All patients were advised to have povidone iodine mouth wash in the day before operation. Under general anesthesia, trans-nasal endotracheal tube, patient lies in supine position with shoulder elevation and head stabilized by ring cushions. Mouth irrigation with saline and wash with povidone iodine. ordinary surgical instruments were used for mouth opening and tongue retraction to the opposite side. Two assistants were required to keep the field exposed.

Local injection of lidocaine and diluted epinephrine 1/80,000 in the submucosal plane (Fig. 1). Dexamethasone ampoule was injected parenterally prior to dissection around nerves in oral floor. Incision of mucosa from papillary caruncle to reach opposite the retromolar area, 1-2 cm medial to mandibular border (Fig. 2). Elevation of medial and lateral flaps to expose the sublingual gland. Blunt dissection of sublingual gland from its anterior end backwards. Excision of sublingual gland to evacuate the sublingual triangle except for submandibular duct and lingual nerve. Both structures are running over mylohyoid muscle.

Handling of submandibular duct starts by mobilizing its orifice and then distal to proximal dissection (Fig. 3). Then uncrossing the duct from lingual nerve (Fig 4) to put the duct laterally while the nerve is maintained medially toward the tongue to avoid undue stretching during the following steps. Further dissection of the lingual nerve from its ganglion was done to make it free.

Gentle upward traction of duct synchronous with extraoral upward pushing through submandibular area to facilitate gland exposure and delivery into oral cavity. Freeing the deep lobe from mylohyoid muscle then anterior retraction of muscle border. The last step brings the swelling more toward operative field. Meticulous bit by bit dissection around the posterior pole of the gland where we suspect to deal with facial vessels. Bipolar diathermy was the main hemostatic instrument, sometimes required ligation.

Further blunt dissection with judicious bipolar cauterization to completely extract the gland. Inspection for hemostasis and then wound irrigation. Hypoglossal nerve appears deep in the wound bed after gland removal. Closure of mucosa with loose stitches. External (extraoral) compression packs over the submandibular area.

Post-operative follow-up:

Collection of post-operative data as tongue sensation, tongue movements, wound healing, wound bleeding, wound infection, and final pathology.

Results:

Transoral sialoadenectomy was performed on 20 patients, 8 men (40%) and 12 women (60%). The mean age was 33.83 years (17.1–51.6 years) (Table 1).

In this study, 13 patients (65%) showed evidence of calculi submandibular sialadenitis, 4 patients (20%) with non calculi submandibular sialadenitis, and 3 patients (15%) with pleomorphic adenoma (Table 1).

All cases were presented with small mobile gland. The mean lump size was 16.4 mm (12-20 mm). All patients passed the 3-finger test to evaluate maximal mouth opening (Table 1).

In the early phase of this study synchronous with still little experience in this approach, two cases (10%) showed difficult dissection due to dense adhesions. Hard dissection complicated by glandular fragmentation and unaccepted hemostasis. Conversion to standard transcervical approach was accomplished in both cases (Table 2).

The mean operative time was 93.75 min (range 55–125 min). The mean duration of hospital stay was 2.75 days (ranged from 2-5 days). Healing time was 14–23days (Table 2).

Two patients (10%) developed wound infection, treated with transoral drainage and antibiotics after culture and sensitivity. Those patients showed delayed wound healing (30 and 35 days).

Five cases (25%) developed abnormal tongue tip sensation that gradually disappeared after 2-3 weeks. No patients developed limitations in tongue movement either early or late. Early limitations in tongue movement are attributed to hypoglossal nerve affection. While late tongue movement affection usually related to the developed scar in the floor of mouth (Table 2).

Discussion:

Modern surgery launched many bright topics as Minimal Invasive Surgery, Scarless Surgery, and Natural Orifice Surgery. All these efforts are trying to deliver the surgical therapy in less morbidity, more efficacy, and better patient satisfaction.

Before 1960, a dental surgeon noticed the feasibility to remove the submandibular gland with natural orifice transoral approach. This new concept was kept unfamous till the beginning of 21st century.

In this study, we started to perform transoral sialoadenectomy for selected cases. Many points were considered for patient selection. All cases with malignant suspicion are excluded from this study for fear of malignant dissemination.

Lump size was the second point for selection. Lumps more than 2 cm, and lumps with limited mobility are excluded. These parameters match the Chang et al findings(4).

This parameter was found to be helpful, as we did not find difficulty in gland removal specially after the initial phase in this study.

Transoral approach for submandibular sialoadenectomy eliminates the visible neck scar plus eliminating the risk of marginal mandibular nerve injury. The main risk in this approach is the liability to injure the lingual nerve. In this study, we found lingual nerve paresthesia in 25% of cases. Fortunately, this paresthesia improved after 2-3 weeks. Other papers reported higher incidence of lingual nerve affection. 74% by Hong et al(7), 50% by Hong et al(12), 43% by Weber et al(13), 25% by Kauffman et al(14).

In this study, the relatively low incidence of lingual nerve affection may be attributed to our protocol for dexamethasone injection before nerve dissection. The same strategy with recurrent laryngeal nerve during thyroidectomy. Also, the step of uncrossing the nerve and Wharton's duct. This step minimizes the undue traction over the lingual nerve.

The hypoglossal nerve is almost far from being injured during transoral approach as it lies deep in the bed. Hypoglossal nerve injury is presented with early affection of tongue movement. On the other hand, late affection of tongue movement due to the formed scar in oral floor and possible injury of extrinsic tongue muscles(7). In this study, no early or late affection of tongue movement. Preserving mucosal margins enables edge-to-edge mucosal suturing in the end of procedure. This may help to achieve primary intention healing with minimal scar tissue formation. Weber et al and Kauffman et al reported no limitation of tongue movement(13,14). While Hong et al and Hong et al reported tongue movement limitation in 70% and 40% in their first and second papers respectively(7,12).

In this study, no cases with much bleeding intraoperatively or postoperatively. Slow meticulous dissection and bipolar coagulation of small blood vessels offer the reliable hemostasis. Two cases (10%) suffered from wound infection and subsequent wound dehiscence. Hong et al (7)reported bleeding in 2.6% and postoperative infection in 2.6%. Their cases with postoperative bleeding presented with immediate postoperative swelling in submandibular area. Urgent return to OR for wound exploration. One case was controlled through intraoral approach, while the other case required external transcervical approach for proper control.

Conclusion:

External transcervical approach for submandibular sialoadenectomy is still the standard approach. In selected cases, transoral approach can be a good alternative specially with those patients who are strongly appreciating scarless operations as young age females.

References:

1. P. P. Singh, M. Goyal. Our Experience with Intraoral Submandibular Gland Excision 2020. *Indian J Otolaryngology Head Neck Surg.* 2020;72(3):297–301.
2. Pasquale Capaccio, Filippo Montevecchi, Giuseppe Meccariello, Giovanni Cammarato, Jeffery Scott Magnuson, Stefano Pelucchi, et al. Transoral Robotic Submandibular Sialoadenectomy: How and When? *Gland Surgery.* 2020;9(2):423–9.
3. Downton D, Qvist G, London FRCS. Intra-oral Excision of the Submandibular Gland. *Proceedings of the Royal Society of Medicine.* 1960;53:9–10.
4. Ying-Nan Chang, Chaun-Hsiang Kao, Yaoh-Shiang Lin, Jih-Chin Lee. Comparison of the intraoral and transcervical approach in submandibular gland excision. *Eur Arch Otorhinolaryngol.* 2013;270:669–74.
5. Giovanni Cammarato, Claudio Vicini, Filippo Montevecchi, Anna Bonsembiante, Giuseppe Meccariello, Lorenzo Bresciani, et al. Submandibular gland excision_ From external surgery to robotic intraoral and extraoral approaches. *Oral Diseases.* 2020;26:853–7.
6. Seung Wook Jung, Young Hoon Cha, Yoon Woo Koh, Woong Nam. Robot-assisted submandibular gland excision via modified facelift incision 2017. *Maxillofacial Plastic and Reconstructive Surgery.* 2017;39(25).
7. Hong KH, Yang YS. Surgical results of the intraoral removal of the submandibular gland. *Otolaryngology - Head and Neck Surgery.* 2008 Oct;139(4):530–4.
8. Beahm DD, Peleaz L, Nuss DW, Schaitkin B, Sedlmayr JC, Rivera-Serrano CM, et al. Surgical approaches to the submandibular gland: A review of literature. Vol. 7, *International Journal of Surgery.* 2009. p. 503–9.

9. Capaccio P, Montevecchi F, Meccariello G, Cammaroto G, Magnuson JS, Pelucchi S, et al. Transoral robotic submandibular sialoadenectomy: How and when. *Gland Surgery*. 2020 Apr 1;9(2):423–9.
10. Khalid H. Zawawi, Emad A. Al-Badawi, Silvia Lobo Lobo, Marcello Melis, Noshir R. Mehta. An Index for the Measurement of Normal Maximum Mouth opening. *J Can Dent Assoc*. 2003;69(11):737–41.
11. Agrawal J, Shenai PK, Chatra L, Kumar PY. Evaluation of normal range of mouth opening using three finger index: South India perspective study [Internet]. Available from: <https://www.ijdr.in/text.asp?2015/26/4/361/167638>
12. Hong KH, Yang YS. Intraoral approach for the treatment of submandibular salivary gland mixed tumors. *Oral Oncology*. 2008 May 1;44(5):491–5.
13. Weber SM, Wax MK, Kim JH. Transoral excision of the submandibular gland. *Otolaryngology - Head and Neck Surgery* [Internet]. 2007 Aug [cited 2021 Dec 6];137(2):343–5. Available from: https://www.researchgate.net/publication/6173455_Transoral_Excision_of_the_Submandibular_Gland
14. Kauffman RM, Nettekville JL, Burkey BB. Transoral excision of the submandibular gland: Techniques and Results of nine cases. *Laryngoscope*. 2009 Mar;119(3):502–7.

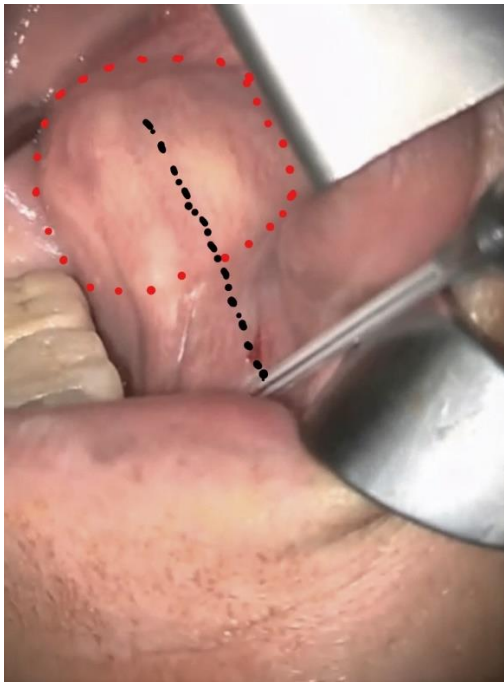


Figure 1 Submucosal injection of Local Anesthetic with Adrenaline

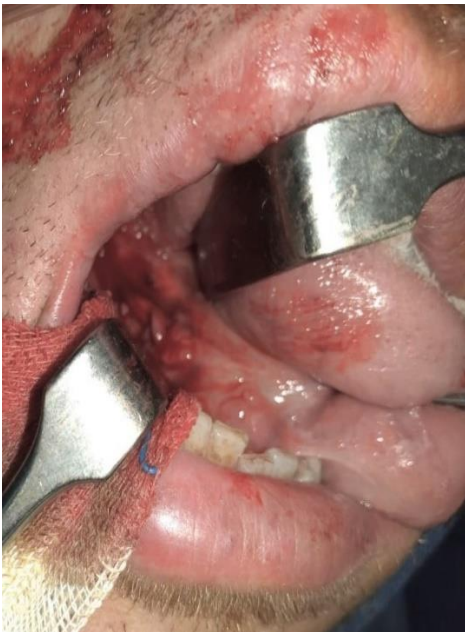

Figure 2 Starting the Mucosal Incision.

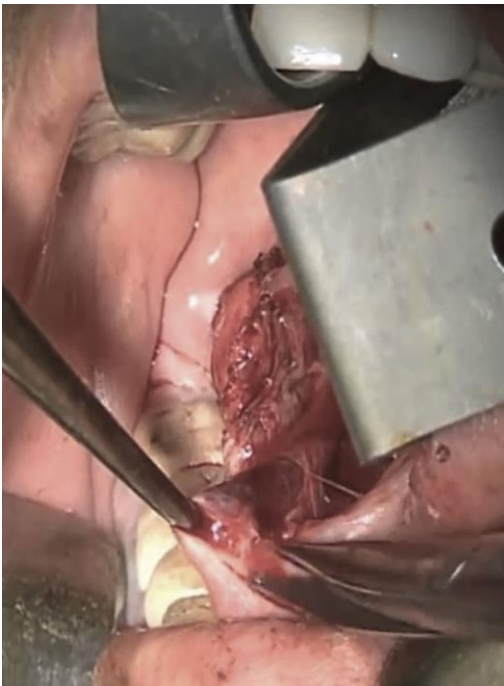

Figure 3 Submandibular Duct Dissection, distal to proximal approach.

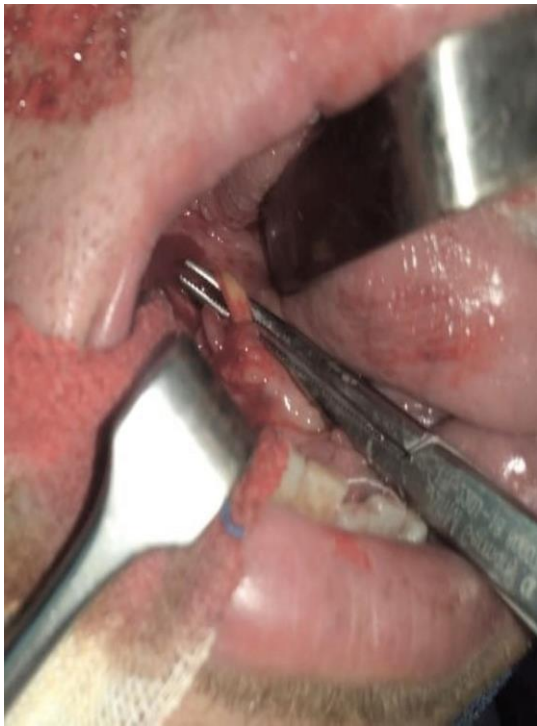

Figure 4 Lingual Nerve medialization after uncrossing with the duct.

Table (1): Preoperative data (Original)		
Gender	Male	8 (40%)
	Female	12 (60%)
Age (y)		33.83 (17.1-51.6)
Pathology	Sialolithiasis	13 (65%)
	Sialadenitis	4 (20%)
	Pleomorphic adenoma	3 (15%)
Gland size (mm)	16.4 (12-20)	

Table (2): Operative and Postoperative Data (Original)

Operative time (min)	93.75 (55-125)
Transcervical Conversion	2 (10%)
Hospital Stay (days)	2.75 (2-5)
Healing Time (days)	14-23
Wound infection	2 (10%)
Abnormal Tongue Sensation	5 (25%)
Limited Tongue Movement	0